



Review

Uterus transplantation: An update and the Middle East perspective



Randa Akouri^{a,b}, Ghassan Maalouf^c, Joseph Abboud^c, Abbo Waked^c, Toufic Nakad^c, Farid Bedran^c, Gael Abou Gjannam^c, Pascal Hajj^c, Ash Hanafy^d, Filip Brännström^a, Shafaq Merzah^a, Manda Gharhemani^e, Pernilla Dahm-Kähler^b, Mats Brännström^{a,b,*}

^aStockholm IVF, Stockholm, Sweden

^bDepartment of Obstetrics and Gynecology, Sahlgrenska Academy, University of Gothenburg, Sweden

^cBellevue University Medical Center, St. Joseph University, Beirut, Lebanon

^dDepartment of Obstetrics and Gynecology, Bond University, Gold Coast, and John Flynn Hospital, Tiguan, Australia

^eSouthern California Medical Group, Kaiser Permanente, LA, CA, USA

ARTICLE INFO

Article history:

Received 23 March 2017

Revised 6 April 2017

Accepted 7 April 2017

Available online 21 April 2017

Keywords:

Human

Infertility

Transplantation

Uterus

ABSTRACT

Uterus transplantation (UTx) is the only available treatment for absolute uterine factor infertility (AUI), which is caused by either absence (congenital or after hysterectomy) or presence of a non-functioning uterus. Uterus transplantation became a clinical reality after more than 10 years of structured animal-based research. Aside from gestational surrogacy, this procedure is the only alternative for women with AUI to attain genetic motherhood. In the Middle East, North Africa and Turkey (MENAT) region, out of a population of around 470 million, more than 100,000 women of fertile age are estimated to suffer from AUI. Introduction of UTx as an infertility treatment in this region will certainly differ in specific countries from ethical, religious and legal standpoints depending on culture and religion. The MENAT region is the cradle of three religions and the geographic area encompasses a variety of cultures and religions with different views on assisted reproduction. In light of these issues, the aim of this article is to give an overview of the research-based development of UTx and its clinical results up until today as well as to explore how UTx would fit into current infertility treatments in the MENAT region, with its existing multifaceted religious perspectives.

© 2017 Middle East Fertility Society. Production and hosting by Elsevier B.V. This is an open access article under the CC BY-NC-ND license (<http://creativecommons.org/licenses/by-nc-nd/4.0/>).

Contents

1. Introduction	164
1.1. Potential patient groups for UTx	164
1.2. Guidelines for research and development towards human UTx	164
2. Animal-based UTx research and human UTx	164
2.1. Rodents	164
2.2. Domestic species	165
2.3. Nonhuman primates	165
3. Preclinical human UTx studies	165
4. Human UTx	165
5. Religious-societal aspects of UTx in the Middle East region	167
5.1. Islam and UTx	167
5.2. Christianity and UTx	167
5.2.1. Catholicism	167
5.2.2. Orthodox denomination	167
5.3. UTx and Judaism	167
6. Preparations for the first clinical UTx-center trial in the Middle East	168

Peer review under responsibility of Middle East Fertility Society.

* Corresponding author at: Stockholm IVF, HammarbyAllé 93, SE-12053 Stockholm, Sweden.

E-mail address: mats.brannstrom@obgyn.gu.se (M. Brännström).

<http://dx.doi.org/10.1016/j.mefs.2017.04.003>

1110-5690/© 2017 Middle East Fertility Society. Production and hosting by Elsevier B.V.

This is an open access article under the CC BY-NC-ND license (<http://creativecommons.org/licenses/by-nc-nd/4.0/>).

Conflict of interest	168
Financial support and sponsorship	168
References	168

1. Introduction

Absolute uterine factor infertility (AUI) has for many years been regarded as untreatable. We reported the first live birth after UTx in 2014 [1] and this has been followed by more births [2]. Thus, UTx is now established as the first treatment for AUI. Historically, there were early attempts to develop UTx with the hope of reaching clinical application. These experiments included transplantation of grafts including the uterus and the oviducts in dogs [3] and nonhuman primates during the 1960s and 1970s [4]. The primary aim was to develop treatment for tubal factor infertility (TFI) and the uterus was included in the graft to simplify surgery. However, the lack of effective immunosuppression (IS) drugs at that time was central in the failure of these pioneering experiments.

After worldwide spread of IVF in the 1980s, TFI became treatable and the interest in UTx-research ceased. Introduction of the first effective IS, cyclosporine, in the mid-1980s, gave rise to a substantial expansion of the clinical field of transplantation surgery. Today even highly immunogenic tissues such as intestines and vascularized composite tissues (hand and face) are transplantable. All existing types of transplants are intended for lifelong use and with continued IS. In this regard, UTx is unique as an ephemeral type of transplantation. Thus, the allograft would just be in the recipient for a restricted time. After the recipient has delivered the number of children desired, hysterectomy should be performed. The recipient can then discontinue IS medications and thereby avoid the IS-related long-term side effects, such as nephrotoxicity [5], as well as increased risks for serious viral, fungal and bacterial infections and certain malignancies [6,7]. The two first UTx attempts in the world were performed in 2000 and 2011 and both took place in the MENAT region [8,9]. Although, these attempts did not result in any births, they paved the way for our clinical trial in Gothenburg, Sweden which included nine patients undergoing UTx in 2013 [10]. The results of all these attempts will be discussed in detail below.

1.1. Potential patient groups for UTx

The causes of permanent AUI [11] are listed in Table 1. It is estimated that around 15,000 AUI patients exist in the UK [12] and this would, on a population-basis, correspond to around 100,000 in the MENAT region.

1.2. Guidelines for research and development towards human UTx

The modern research preparations in UTx span over more than a decade [13,14] and follow the IDEAL (Innovation, Development, Exploration, Assessment, Long-term follow up) concept [15], which emphasizes a structured and research-based introduction of any novel, major surgical procedure. This approach minimizes the risks for the patients but also accumulates important scientific data during clinical introduction. Currently, UTx is in the D (Development) phase of the IDEAL concept with our observational study, including nine patients [10]. An International Society for Uterus Transplantation (ISUTx) was recently formed at a meeting in Gothenburg Sweden. This society has initiated the formation of an international registry, to follow all patients (donors, recipients, and children)

to accumulate data to also explore the L (Long-term follow-up) phase of the IDEAL concept.

It is necessary that information concerning all ongoing human UTx research and its results reach the public in all countries and societies so that all are informed about this potential new fertility treatment, which also may raise some ethical concerns. It should be mentioned that Federation International Gynecology and Obstetrics (FIGO) launched ethics principles of UTx already in 2009 and these emphasizes that animal experiments is an obligatory component [16].

2. Animal-based UTx research and human UTx

Modern attempts in animal-based UTx research stems from the early 2000s and initially involved smaller rodents, later large domestic species and from around 2005 nonhuman primates [13,14,17]. The key findings of this research are summarized below.

2.1. Rodents

The initial rodent UTx model was the mouse, with the first ever pregnancy after UTx demonstrated already in 2002 [18] and in 2003 we reported the first offsprings [19]. This was in a syngeneic setting (between inbred strains) and consequently IS was not needed. Offspring exhibited normal postnatal growth trajectory and were fertile. The uterus was tolerable to 24 h of cold ischemia, between harvesting from the donor until UTx, since the majority of these cold-preserved and transplanted uteri achieved normal pregnancy and offspring [20]. Additional mouse UTx-studies, characterized rejection after allogeneic transplantation by examining the morphology, blood flow [21], influx of specific subclasses of leukocytes [22,23] as well as influence of immunosuppression by cyclosporine [24].

Table 1

Causes of uterine factor infertility that may be treatable by uterus transplantation.

<i>No uterus</i>
• Congenital uterine absence (Müllerian/Mayer-Rokitansky-Küster-Hauser (MRKH)-syndrome)
• Hysterectomy
– Cervical/uterine malignancy
– Leiomyoma
– Obstetric bleeding
– Atony
– Malplacentalion (placenta accrete/percreta)
– Uterine rupture
<i>Uterus present</i>
• Leiomyoma
• Adenomyosis
• Multiple miscarriages/implantation failures
• Radiation damage
• Uterine malformation
– Fraction of unicornuate uterus
– Fraction of bicornuate uterus
– Hypoplastic uterus
• Cervical incompetence with multiple miscarriages
– Post multiple conisation procedures
– Post trachelectomy procedure
• Severe intrauterine adhesions, untreatable by hysteroscopy

We introduced the rat UTx model some years later, with the advantages of this model being the larger size of the vasculature and that therapeutic blood concentrations of IS are in the same range as in the human, as opposed to the mouse, with much higher therapeutic levels. The uterus was transplanted into an orthotopic position, with vascular anastomoses to the common iliacs, to allow for natural conception in the initial syngeneic rat-UTx model [25]. Although similar pregnancy rates were noted in the UTx group and control group, there was a high rate of arrested parturition after UTx [26]. Studies were also performed to find the optimal IS in the allogeneic rat UTx model and tacrolimus was found to be superior to cyclosporine to prevent rejection [27,28]. Pregnancies were demonstrated after allogeneic UTx under tacrolimus IS and normal growth of these offspring was seen [29,30].

2.2. Domestic species

Both the pig and sheep have been used in UTx research, with the advantage being their larger body size and consequently with dissection of the uterine vasculature that resemble the anatomical situation in the human. However, a difference is that both these species have bicornuate uteri. Our initial sheep UTx model was with excision of one uterine horn and at auto-UTx, anastomosis was performed to the ipsilateral external iliac vessels [31,32]. After utero-ovarian autotransplantation, with undisturbed connections of the utero-tubal-ovarian compartment, mating occurred and live offsprings were demonstrated [33]. The Ramirez group performed allogeneic UTx in the sheep, with end-to-end anastomosis on the uterine vessels and long-term uterine survival was seen with cyclosporine IS [34]. One live birth was demonstrated in a follow-up study [35]. Another group showed graft survival for two months after allogeneic UTx with bilateral end-to-end vascular anastomoses on uterine arteries/utero-ovarian veins and with a triple IS protocol of tacrolimus, mycophenolate mofetil (MMF) and methylprednisolone [36]. In the pig UTx model, initial auto-UTx studies examined reperfusion events [37] and vascular patency some weeks after transplantation [12]. In the latter study, the graft was reintroduced after 1 h of cold storage and this was followed by stepwise vascular reanastomosis. Graft survival was seen for 3 months but with signs of gradual thrombosis formation. Later, long-term survival of the allogeneically transplanted miniswine uterus was seen after IS with intra venous tacrolimus for 12 days which was followed cyclosporine and with a transplantation technique of a macrovascular aorto-caval patch, with the uterus heterotopically positioned [38].

2.3. Nonhuman primates

The obvious advantage of a nonhuman primate species in UTx research is the human-like immunology as well as reproductive anatomy/physiology. In our initial studies utilizing auto-UTx in the baboon, restored menstruation was only seen in 20% of animals [39]. After modification of methodology in relation to flushing of the graft and anastomosis surgery a 3-fold higher success rate was accomplished [40]. In allogeneic UTx in this species, with transplantation from live donors, recovery surgery lasted for 3.5 h and donor survival was 100% [41]. The best IS protocol was induction with antithymocyte globulin, followed by triple maintenance IS with tacrolimus, MMF and corticosteroids [41]. Importantly, a rejection-grading system, based on histology of cervical biopsies, was developed in this allogeneic baboon UTx model [41,42].

Initial studies in the smaller cynomolgus macaque, with bilateral anastomosis of the uterine artery and the deep uterine vein to the external iliacs demonstrated resumed menstruation [43]. It was also shown that the complete macaque uterus is adequately

perfused with use of only unilateral anastomoses [44]. Importantly, the first UTx pregnancy and live offspring, albeit after auto-UTx, in a primate species was shown in the cynomolgus macaque [45]. Moreover, a surgical procedure using the ovarian vein for outflow demonstrated adequate perfusion after UTx and it was concluded that this technique could potentially simplify live-donor surgery in UTx [46]. However, it should be noted that pregnancies have not been demonstrated in this model, using the ovarian veins. A problem may be tension of these veins during the progressive uterine growth during pregnancy, especially if the anastomosis sites are on the external iliacs, which are relatively low in the pelvis. Recently, it was demonstrated that after allo-UTx in the macaque, with triple IS therapy (tacrolimus, MMF and methylprednisolone), there was recovery of menstruation around three months after surgery [47].

3. Preclinical human UTx studies

There has been a small number of preclinical UTx studies by the use of human material. We assessed the tolerability to cold ischemia of myometrial tissue-pieces from hysterectomy specimens and found that the ultramorphology of the myometrial cells were well preserved after 6 and 24 h of cold ischemia and spontaneous, as well as prostaglandin-augmented, myometrial contractions were still present [48]. Two studies investigated uterine recovery from brain-dead donors. In the initial study, performed in USA, uterine donation with a research purpose was only accepted by the relatives of the brain-dead women in 6% of cases [49]. The other study was performed in France, almost a decade later [50], when the concept of human UTx was known to the public after initial success of human UTx cases [1,9]. In that study, with a much higher (50%) acceptance rate, organ retrieval procedure was performed in seven female multiorgan donors. The uterus was removed together with the hypogastric vessels, parametria, and vaginal fornices. They found no major morphologic changes in the myometrium after 24 h of cold ischemia and the hypogastric vessels could be preserved in all cases but one with unilateral vein loss. Severe desquamation of the endometrium was seen after 24 h of cold ischemia but apoptotic cells were rare.

In a live donor UTx procedure, it is more difficult to acquire long vascular pedicles. We explored this issue in a study of patients undergoing radical hysterectomy surgery and with added separate dissections of uterine arteries and veins [51]. The accomplished lengths of the uterine arteries and veins were above 5 cm, which would enable bilateral end-to-side anastomosis to the external iliacs, since they are around 9 cm apart at the level of the uterus [51].

4. Human UTx

The first ever attempt of human UTx was performed in Middle East, more precisely in Jeddah, Saudi Arabia in April 2000 [8]. The donor, a 46-year-old, premenopausal woman presenting with large bilateral ovarian cysts, underwent hysterectomy and bilateral salpingo-oophorectomy. The recipient, a 26-year-old woman, had undergone emergency peripartum hysterectomy due to massive hemorrhage at a cesarean section six years prior.

Donor hysterectomy was modified with fairly short vascular pedicles of the uterine arteries and veins. A ureteric laceration occurred and it was immediately repaired. Upon retrieval, the uterus with attached oviducts was flushed with cold Euro-Collins solution. Extensive back-table surgery was performed by anastomosing 6–8 cm long saphenous venous grafts in end-to-end manners on uterine veins and as reversed grafts on uterine arteries.

Laparotomy of the recipient commenced when donor graft retrieval was imminent. The donor uterus was placed in the ortho-

topic position with the extended uterine arteries and veins anastomosed end-to-side to the external iliacs. Cyclosporine, corticosteroids and azathioprine were used as maintenance IS.

One possible episode of rejection was observed on day nine post-surgery and was treated by antithymocytic globulin. The uterus did not show spontaneous menstruation. On day 99 post-surgery the transplant recipient presented with pelvic heaviness and vaginal discharge. Doppler examination could not detect uterine blood flow. Hysterectomy was performed and histopathology confirmed blood flow cessation with infarction. Albeit a graft failure, this first human UTx case, performed in the Middle East, advanced the field considerably by demonstrating the feasibility of uterine donation from a live donor. However, it was clear that further animal-based research was necessary before any new clinical attempt should be performed.

The second human UTx was also performed in the MENAT region. In August 2011, a 21-year old MRKH-patient was transplanted with a uterus from a 22-year-old brain-dead, heart beating donor in Antalya, Turkey [9]. The recovery with the uterus as the first organ to be retrieved, took 2 h and the transplantation procedure, including bilateral end-to-side anastomosis of the common iliacs of the graft to the recipient's external iliac vessels, lasted 6 h. The initial IS included daily thymoglobulin for 10 days followed by maintenance IS with tacrolimus, prednisolone and MMF. Today, five years after transplantation, the uterus is still in place. The multiple ET attempts that have been performed have resulted in only two early miscarriages [52]. The reason for the pregnancy failures is not clear but it may well be related to uterine-specific factors rather than embryo-specific factors, since the recipient is of young age. Notable is that the young transplanted uterus had not carried a pregnancy before UTx, and there may exist uterine-specific anatomical or biochemical factors that impair implantation or continued pregnancy.

In Gothenburg, Sweden, we performed nine live-donor UTx procedures in early 2013 [10]. Eight recipients had the MRKH syndrome and one had undergone a radical hysterectomy because of stage Ib1 cervical cancer. The patients went through 2–3 IVF cycles prior to UTx in order to cryopreserve embryos. The donors were mothers in five cases, one older sister, one maternal aunt, one mother-in-law and one close friend. Five donors that were post-menopausal received cyclic estrogen-progestagen treatment for 2–3 months before surgery, in order to ensure normal menstrual patterns and to possibly increase uterine artery blood flow before donation. The donors, recipients and partners of recipients were

extensively investigated for several months before UTx to ensure that they were medically and psychologically fit for participation [10,53]. The donor surgery [10] was performed by a midline incision with initial dissection of the uterus, excluding ovaries and oviducts, on the frontal aspect to include an extensive bladder peritoneum. Ureteric dissection, without confronting the adjacent uterine vessels, was performed from the pelvic brim to the bladder. Bilateral vascular pedicles, including the internal iliac arteries distal to the branchings of the gluteal arteries as well as the major uterine veins down to, and including a part of the internal iliac vein, were dissected (Fig. 1). The rectovaginal space was then opened and the uterus, with long bilateral vascular pedicles was isolated and brought to the back-table (Fig. 1). Donor surgeries lasted 10.5–13 h, but no perioperative blood transfusions were required and with hospital stay of 6 days in all cases. In one patient a ureteric-vaginal fistula was diagnosed two weeks after the hysterectomy and this was later successfully repaired.

The recipient surgery included bilateral end-to-side anastomoses to the external iliacs, anastomosis to the vagina and uterine fixation to several pelvic ligaments (Fig. 1). The IS regimen was induction with two perioperative doses of thymoglobulin. From the day of surgery also tacrolimus and MMF were given daily and glucocorticoids were administered for one week. After eight months, MMF was discontinued if no or only one rejection episodes had occurred during this period, but was replaced with azathioprine in patients with several rejection episodes. The 6-months outcome was that seven out of nine uteri were still in place. One uterus was removed after three days because of bilateral thrombosis of the uterine vessels in a recipient with heterozygosity for the Leiden mutation. The second uterine removal was because of an intrauterine infection, that developed into an abscess and septicemia, despite heavy iv antibiotic treatments and several attempts of surgical drainage [10]. These two graft failures occurred in two out of the three uteri that were above age 60 at transplantation and also in one case with the lowest uterine blood flow after transplantation.

The seven remaining uteri showed spontaneous and regular menstruation beginning 1–2 months after UTx [54] and uterine artery blood flow was within normal ranges. Subclinical, mild rejection episodes were diagnosed on protocol cervical biopsies in five out of seven women [54].

The psychological outcome during the first post-transplantation year of recipients and partners was an overall optimism but with minor anxiety around graft survival around three months post

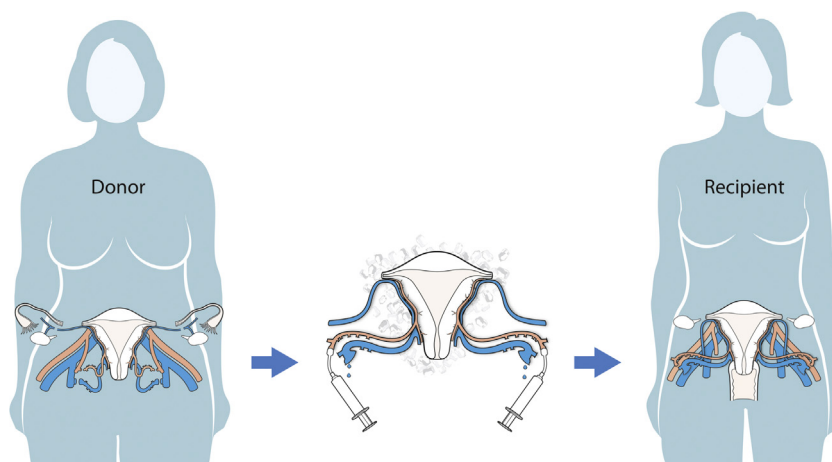


Fig. 1. Schematic drawing of the live donor uterus transplantation procedure. The Donor surgery (Left) involves harvesting of the uterus with long vascular pedicles, including segment of the internal iliac arteries and veins. The Uterus (middle) is chilled and flushed on the back-table (central image). The Recipient surgery (right) involves bilateral vascular anastomoses to the external iliac artery and vein.

UTx [55]. Single ETs were performed from 12–14 months after UTx. Two women became pregnant at their first ET and the first live birth after UTx took place September 4, 2014 [1]. Preeclampsia developed at gestational week 31+5 in this MRKH patient with a single kidney and delivery was by cesarean section the following day. Although this was patient number five of the UTx trial and the seventh UTx attempt worldwide, the case represents the first UTx procedure that by definition is successful. The second UTx-baby born was from a mother-to-daughter UTx and delivery of a healthy baby was by cesarean section in week 34+6 [2]. Preeclampsia did not develop in this mother, with double kidneys. However, preeclampsia has developed in two out of three of the subsequent births and only in MRKH mothers with single kidneys (unpublished observations). It is likely that the single kidney is the strongest risk factor for preeclampsia development after UTx, even if the MRKH-setting and other factors such as aged uterus, IS and IVF may contribute [56]. So far five out of seven patients from our cohort that have undergone UTx and ET have delivered healthy babies, with one giving birth twice. Two more pregnancies are ongoing and expected to deliver in early summer 2017 (our unpublished data).

5. Religious-societal aspects of UTx in the Middle East region

In general, the capacity to have offspring has always been an undeniably significant aspect of human existence. The ethical layers of UTx as a clinical treatment will vary depending on the culture and religion of each specific society. In the Middle East, the site of origin of the three major religions: Judaism, Christianity and Islam, the beliefs are stronger than in many other parts of the world.

5.1. Islam and UTx

For Middle Eastern Muslims, formation of family with children is highly desirable as parenthood is culturally mandatory. In that regard, many alternative reproductive technologies are being explored to reduce the effects of infertility. Unlike many other parts of the world, the new medical technologies are practiced according to religious guidelines. Not only are Islamic religious authorities keen to establish the limitations within which ART is and is not acceptable, but many infertile Muslim couples are also progressively more open to pursuing ART in seek of parenthood in the acceptable and religiously endorsed manner. Islam permits reproduction only using the genetic material of intended parents. Thus IVF, insemination and embryo cryopreservation, with use of gametes of its lawfully married parents, are permissible [57]. The Sunni sect is the most prevalent form of Islam (about 90% of the world's Muslims). While, all Sunnis consider surrogacy as prohibited, Shia Muslims believe otherwise. In 1999, a fatwa allowing donor technologies in ART to be used was introduced in the Islamic republic of Iran, permitting not only surrogacy but also sperm donation, egg donation, and embryo donation [58].

Concerning transplantation of reproductive tissues, the Islamic Fiqh Council conference held in the sixth cycle in Jeddah in Saudi Arabia in 1990 came to several conclusions after studying the research and recommendations on the subject, and in collaboration with the Islamic Organization for Medical Sciences. Transplantation of gonads (testis and ovary) that carry genetic traits is forbidden in Islam. Second, transplantation of parts of the reproductive system that does not transfer genetic traits e.g. the uterus is legal and legitimate in accordance with the regulations and standards set out in the legitimacy. Moreover, the majority of Islamic legal scholars have concluded that transplantation of organs as treatment for otherwise lethal end-stage organ failure is a good thing.

Donation by living donors and by deceased donors is not only permitted but encouraged [59].

5.2. Christianity and UTx

5.2.1. Catholicism

The accustomed principle, referred to in the Catechism of the Catholic Church, that the morals of an individual act depend on three factors (the object, the end, and the circumstances) involved, can be applied on introduction of new medical technologies. An act is morally good only if all three of these factors are morally good. Paragraph 2376 of the Catechism of the Catholic Church states that: "Techniques that entail the dissociation of husband and wife, by the intrusion of a person other than the couple (donation of sperm or ovum, surrogate uterus), are gravely immoral [60]. Regarding UTx, they state it as "good" way to restore a woman's infertility by transplanting a healthy womb in situations where she lacks one. But the action by pursuing a pregnancy through in vitro fertilization (IVF) would render it as immoral, since IVF represents a morally disordered means of engendering new human. Only under the circumstances where a transplanted uterus, either from a deceased or a live donor, to another woman whose ovaries and Fallopian tubes would function normally so she could conceive a child by normal way the womb transplant could probably represent an ethical means of resolving the AUI [61].

5.2.2. Orthodox denomination

The Holy Tradition of the Orthodox Church does not refer directly to new reproductive technologies. Nevertheless, a number of Orthodox writers have addressed them. These authorities generally maintain a powerful respect for life as a gift from God. They furthermore support the Orthodox Church's view of procreation within marriage as the proper expression not only of their physical sexual relationship, but also of whole spiritual, familial, and social relationships [62]. On the other hand, since death ends the personal physical relationship of spouses, the Church does not support various methods of postmortem conception for example implantation of frozen fertilized ova. One reason given for this prohibition is the moral, relational, social, and spiritual confusion that such practices provoke. For similar reasons, the Orthodox Christian Church also fundamentally opposes all forms of surrogate motherhood [63], which may speak in favor of UTx.

An Orthodox Christian should not be pressured to violate personal convictions if they do not wish to donate an organ or receive an organ transplant, following the provision of adequate information. Nevertheless, the Orthodox church would accept organ donation as a way to better human life to improve and prevent a disease by using transplantation or research. In some predominantly Orthodox nations, the Church has supported organizations that foster the practice of organ transplantation as an expression of philanthropy and Christian love [64].

5.3. UTx and Judaism

It is the first and the most important bidding in the Torah to be fruitful and multiply (Genesis 1:28). Infertility is a disorder, so everything is possible in order to alleviate a patient. It is even permitted to break the laws of Shabbat for cure. It is believed that doctors are God's hands blessed with special abilities and understanding to alleviate ailing humans and every Jew has to yield affliction of his or her health, and has to do his or her bests to receive the greatest possible treatment. Because of the centrality of children in Judaism, and the biblical commandment to be fruitful and multiply, infertility is often especially painful for Jewish couples. Societal norms in the observant Jewish community - such

as the tendency to have children soon after marriage and to have larger families with births more closely spaced than is usual in the general society- can add to the pressure. The biblical commandment is fulfilled, by having one son and one daughter. Therefore, it is often assumed that couples are attempting to conceive from the moment of marriage and thus the family and society may become aware of a fertility problem sooner in this patient population than in the general public.

In general, the Jewish beliefs have traditionally taken a doubtful view regarding dead donation. There are three prohibitions concerning cadavers that would seem to prevent deceased organ donation. These are (a) damaging a cadaver, (b) delaying burial of a cadaver, and (c) receiving a profit from a cadaver [65]. This would not apply to the donation of the uterus, which is not a life-saving organ but unlike any other type of transplantable organ a life propagating organ.

According to majority of contemporary scholars UTX using related donor is acceptable in light of the Jewish religious law. Preferably a donor should be at the post-menopausal state, risks to both donor and recipient should be limited as much as possible, and the surgery should be planned well in advance before Shabbat and holidays.

6. Preparations for the first clinical UTX-center trial in the Middle East

Our collaborative group was initiated in 2014 to explore the possibility of performing a trial of UTX in Lebanon. We have worked extensively with protocols for the procedure and with transfer of the UTX technology from Sweden to Lebanon. Surgical training in sheep has been ongoing in Sweden after the human trial to optimize the technique and we will conduct common surgical training sessions involving autotransplantation of the sheep uterus. The sheep is a suitable model, because of similar size of blood vessels and uterus, as the human. Moreover these autotransplantation procedures mimic both organ procurement from live donor and uterus transplantation. The most important aspect is however, the training and exercise of the team work of gynecologists and transplant surgeons so that every surgeon use their expertise when needed and in collaboration with other team-members.

We have chosen to plan for a live donor concept, since surgery can be planned with participants of both the Swedish team and the local Lebanese team. It should also be pointed out that a live donor UTX procedure give ample time for investigations of the suitability of the uterus to be donated. Moreover, the graft survival in renal transplantation is in general superior when the organ is from live donors in comparison to when from deceased donors. This would most likely also apply to UTX, since the systemic inflammation with massive cytokine release that occur at brain death is avoided.

The ethics behind live donor UTX have been reviewed [66] and this is now applied to a setting of the Middle East by ethics discussion and formation of documents. The Bellevue University Medical Center, Ethical Committee (IRB) recognized by the Lebanese Ministry of Public Health has approved this clinical trial pending review of all medical and psychological files of every case undergoing this trial to make sure that all ethical requirements are respected.

Conflict of interest

The authors declare no conflicts of interest.

Financial support and sponsorship

Supported by Jane and Dan Olsson Foundation for Science.

References

- [1] M. Brännström, L. Johannesson, H. Bokström, N. Kvarnström, J. Mölne, P. Dahm-Kähler, A. Enskog, M. Milenkovic, J. Ekberg, C. Diaz-Garcia, M. Gäbel, A. Hanafy, H. Hagberg, M. Olausson, L. Nilsson, Livebirth after uterus transplantation, *Lancet* 385 (2015) 607–616.
- [2] M. Brännström, H. Bokström, P. Dahm-Kähler, C. Diaz-Garcia, J. Ekberg, A. Enskog, H. Hagberg, L. Johannesson, M. Kvarnström, J. Mölne, M. Olausson, J. Olofsson, K. Rodriguez-Wallberg, One uterus bridging three generations: first live birth after mother-to-daughter uterus transplantation, *Fertil. Steril.* 106 (2016) 261–266.
- [3] S. Eraslan, R.J. Hamernik, J.D. Hardy, Replantation of uterus and ovaries in dogs, with successful pregnancy, *Arch. Surg.* 92 (1966) 9–12.
- [4] J.R. Scott, R.M. Pitkin, M.E. Yannone, Transplantation of the primate uterus, *Surg. Gynecol. Obstet.* 133 (1971) 414–418.
- [5] A.M. de Mattos, A.J. Olyaei, W.M. Bennett, Nephrotoxicity of immunosuppressive drugs: long-term consequences and challenges for the future, *Am. J. Kidney Dis.* 35 (2000) 333–346.
- [6] K. Orlicka, E. Barnes, E.L. Culver, Prevention of infection caused by immunosuppressive drugs in gastroenterology, *Ther. Adv. Chronic Dis.* 4 (2013) 167–185.
- [7] J. Dantal, M. Hourmat, D. Cantarovich, M. Giral, G. Blanchot, B. Dreno, J.P. Souillou, Effect of long-term immunosuppression in kidney-graft recipients on cancer incidence: randomised comparison of two cyclosporin regimens, *Lancet* 351 (1998) 623–628.
- [8] W. Fageeh, H. Raffa, H. Jabbar, A. Marzouki, Transplantation of the human uterus, *Int. J. Gynaecol. Obstet.* 76 (2002) 245–251.
- [9] O. Ozkan, M.E. Akar, O. Erdogan, N. Hadimioglu, M. Yilmaz, F. Guneseren, M. Cinlik, E. Pesterelei, H. Kocak, D. Mutlu, A. Dinckan, O. Geccici, G. Bektas, G. Suleymanlar, Preliminary results of the first human uterus transplantation from a multiorgan donor, *Fertil. Steril.* 99 (2013) 470–476.
- [10] M. Brännström, L. Johannesson, P. Dahm-Kähler, A. Enskog, J. Mölne, N. Kvarnström, C. Diaz-Garcia, A. Hanafy, C. Lundmark, J. Marcickiewicz, M. Gäbel, K. Groth, R. Akouri, S. Eklind, J. Holgersson, A. Tzakis, M. Olausson, First clinical uterus transplantation trial: a six-month report, *Fertil. Steril.* 101 (2014) 1228–1236.
- [11] C. Díaz-García, M. Brännström M, Uterus transplantation: potential patients fertility in animal models and ethics, *J. Reproduktions Med. Endokrinol.* 10 (2013) 72–81.
- [12] K. Sieunarine, F.B. Zakaria, D.C. Boyle, D.J. Corless, D.E. Noakes, I. Lindsay, A. Lawson, L. Ungar, G. Del Priore, J.R. Smith, Possibilities for fertility restoration: a new surgical technique, *Int. Surg.* 90 (2005) 249–256.
- [13] A. Hanafy, C. Diaz-Garcia, M. Olausson, M. Brännström, Uterine transplantation: one human case followed by a decade of experimental research in animal models, *Aust. N Z J. Obstet. Gynaecol.* 51 (2011) 199–203.
- [14] M. Brännström, C. Diaz-Garcia, A. Hanafy, M. Olausson, A. Tzakis, Uterus transplantation: animal research and human possibilities, *Fertil. Steril.* 97 (2012) 1269–1276.
- [15] P. McCulloch, D.G. Altman, W.B. Campbell, D.R. Flum, P. Glasziou, J.C. Marshall, J. Nicholl, C. Balliol, J.K. Aronson, J.S. Barkun, J.M. Blazeby, I.C. Boutron, P.A. Clavien, J.A. Cook, P.L. Ergina, L.S. Feldman, D.R. Flum, G.J. Maddem, J.B.C. Reeves, C.M. Seiler, S.M. Strasberg, J.L. Meakins, D. Ashby, N. Black, J. Bunker, M. Burton, M. Campbell, K. Chalkidou, I. Chalmers, M. De Leval, J. Deeks, P.L. Ergina, A. Grant, M. Gray, R. Greenhalgh, M. Jenicek, S. Kehoe, R. Lilford, P. Littlejohns, Y. Loke, R. Madhock, K. McPherson, J. Meakins, P. Rothwell, B. Summerskill, D. Taggart, P. Tekkis, M. Thompson, T. Treasure, U. Trohler, J. Vandenbroucke, No surgical innovation without evaluation: the IDEAL recommendations, *Lancet* 374 (2009) 1105–1112.
- [16] J. Milliez, Uterine transplantation FIGO Committee for the ethical aspects of human reproduction and women's health, *Int. J. Gynaecol. Obstet.* 106 (2009) 270.
- [17] M. Brännström, C.A. Wranning, A. Altchek, Experimental uterus transplantation, *Hum. Reprod. Update* 16 (2010) 329–345.
- [18] R. Racho El-Akouri, G. Kurlberg, G. Dindelegan, J. Mölne, A. Wallin, M. Brännström, Heterotopic uterine transplantation by vascular anastomosis in the mouse, *J. Endocrinol.* 174 (2002) 157–166.
- [19] R. Racho El-Akouri, G. Kurlberg, G. Dindelegan, J. Mölne, A. Wallin, M. Brännström, Successful uterine transplantation in the mouse: pregnancy and post-natal development of offspring, *Hum. Reprod.* 18 (2003) 2018–2023.
- [20] R. Racho El-Akouri, C.A. Wranning, J. Mölne, G. Kurlberg, M. Brännström, Pregnancy in transplanted mouse uterus after long-term cold ischaemic preservation, *Hum. Reprod.* 18 (2003) 2024–2030.
- [21] R.R. El-Akouri, J. Mölne, K. Groth, G. Kurlberg, M. Brännström, Rejection patterns in allogeneic uterus transplantation in the mouse, *Hum. Reprod.* 21 (2006) 436–442.
- [22] K. Groth, R. Akouri, C.A. Wranning, J. Mölne, M. Brännström, Rejection of allogeneic uterus transplant in the mouse: time-dependent and site-specific infiltration of leukocyte subtypes, *Hum. Reprod.* 24 (2009) 2746–2754.
- [23] K. Groth, M. Brännström, J. Mölne, C.A. Wranning, Cyclosporine A exposure during pregnancy in mice: effects on reproductive performance in mothers and offspring, *Hum. Reprod.* 25 (2010) 697–704.
- [24] C.A. Wranning, R.R. El-Akouri, K. Groth, J. Mölne, A.K. Parra, M. Brännström, Rejection of the transplanted uterus is suppressed by cyclosporine A in a semi-allogeneic mouse model, *Hum. Reprod.* 22 (2007) 372–379.

- [25] C.A. Wranning, S.N. Akhi, G. Kurlberg, M. Brännström, Uterus transplantation in the rat: model development, surgical learning and morphological evaluation of healing, *Acta Obstet. Gynecol. Scand.* 87 (2008) 1239–1247.
- [26] C.A. Wranning, S.N. Akhi, C. Diaz-Garcia, M. Brännström, Pregnancy after syngeneic uterus transplantation and spontaneous mating in the rat, *Hum. Reprod.* 26 (2011) 553–558.
- [27] K. Groth, S.N. Akhi, J. Mölne, C.A. Wranning, M. Brännström, Effects of immunosuppression by cyclosporine A on allogeneic uterine transplant in the rat, *Eur. J. Obstet. Gynecol. Reprod. Biol.* 163 (2012) 97–103.
- [28] S.N. Akhi, C. Diaz-Garcia, R.R. El-Akouri, C.A. Wranning, J. Mölne, M. Brännström, Uterine rejection after allogeneic uterus transplantation in the rat is effectively suppressed by tacrolimus, *Fertil. Steril.* 99 (2013) 862–870.
- [29] C. Diaz-Garcia, S.N. Akhi, A. Wallin, A. Pellicer, M. Brännström, First report on fertility after allogeneic uterus transplantation, *Acta Obstet. Gynecol. Scand.* 89 (2010) 1491–1494.
- [30] C. Diaz-Garcia, L. Johannesson, R. Shao, H. Billig, M. Brännström, Pregnancy after allogeneic uterus transplantation in the rat: perinatal outcome and growth trajectory, *Fertil. Steril.* 102 (2014) 1545–1552.
- [31] P. Dahm-Kähler, C. Wranning, C. Lundmark, A. Enskog, J. Mölne, J. Marcickiewicz, R.R. El-Akouri, J. McCracken, M. Brännström, Transplantation of the uterus in sheep: methodology and early reperfusion events, *J. Obstet. Gynaecol. Res.* 34 (2008) 784–793.
- [32] C.A. Wranning, P. Dahm-Kähler, J. Mölne, U.A. Nilsson, A. Enskog, M. Brännström, Transplantation of the uterus in the sheep: oxidative stress and reperfusion injury after short-time cold storage, *Fertil. Steril.* 90 (2008) 817–826.
- [33] C.A. Wranning, J. Marcickiewicz, A. Enskog, P. Dahm-Kähler, A. Hanafy, M. Brännström, Fertility after autologous ovine uterine-tubal-ovarian transplantation by vascular anastomosis to the external iliac vessels, *Hum. Reprod.* 25 (2010) 1973–1979.
- [34] E.R. Ramirez, D.K. Ramirez, V.T. Pillari, H. Vasquez, H.A. Ramirez, Modified uterine transplant procedure in the sheep model, *J. Minim. Invasive Gynecol.* 15 (2008) 311–314.
- [35] E.R. Ramirez, D.K. Ramirez, M.B. Nessetti, M. Khatamee, M.R. Wolfson, T.H. Shaffer, V.Z. Ramirez, H.A. Ramirez, Pregnancy and outcome of uterine allotransplantation and assisted reproduction in sheep, *J. Minim. Invasive Gynecol.* 18 (2011) 238–245.
- [36] L. Wei, T. Xue, H. Yang, G.Y. Zhao, G. Zhang, Z.H. Lu, Y.H. Huang, X.D. Ma, H.X. Liu, S.R. Liang, F. Yang, B.L. Chen, Modified uterine allotransplantation and immunosuppression procedure in the sheep model, *PLoS ONE* 8 (2013) e81300.
- [37] C.A. Wranning, R.R. El-Akouri, C. Lundmark, P. Dahm-Kähler, J. Mölne, A. Enskog, M. Brännström, Auto-transplantation of the uterus in the domestic pig (*Sus scrofa*): surgical technique and early reperfusion events, *J. Obstet. Gynaecol. Res.* 32 (2006) 358–367.
- [38] D.L. Avison, W. DeFaria, P. Tryphonopoulos, A. Tekin, G.R. Attia, H. Takahashi, Y. Jin, E. Palaios, N. Pararas, M.R. Carreno, S. Santiago, F. Bazer, P. Ruiz, A. Tzakis, Heterotopic uterine transplantation in a swine model, *Transplantation* 88 (2009) 465–469.
- [39] A. Enskog, L. Johannesson, D.C. Chai, P. Dahm-Kähler, J. Marcickiewicz, A. Nyachio, J.M. Mwenda, M. Brännström, Uterus transplantation in the baboon: methodology and long-term function after auto-transplantation, *Hum. Reprod.* 25 (2010) 1980–1987.
- [40] L. Johannesson, A. Enskog, P. Dahm-Kähler, A. Hanafy, D.C. Chai, J.M. Mwenda, C. Diaz-Garcia, M. Olausson, M. Brännström, Uterus transplantation in a non-human primate: long-term follow-up after autologous transplantation, *Hum. Reprod.* 27 (2012) 1640–1648.
- [41] L. Johannesson, A. Enskog, J. Mölne, C. Diaz-Garcia, A. Hanafy, P. Dahm-Kähler, A. Tekin, P. Tryphonopoulos, P. Morales, K. Rivas, P. Ruiz, A. Tzakis, M. Olausson, M. Brännström, Preclinical report on allogeneic uterus transplantation in non-human primates, *Hum. Reprod.* 28 (2013) 189–198.
- [42] P. Tryphonopoulos, A.G. Tzakis, A. Tekin, L. Johannesson, K. Rivas, P.R. Morales, J. Wagner, J. Mölne, A. Enskog, C. Diaz-Garcia, P. Dahm-Kähler, M. Berho, S. Zimberg, T. Falcone, P. Ruiz, M. Olausson, M. Brännström, Allogeneic uterus transplantation in baboons: surgical technique and challenges to long-term graft survival, *Transplantation* 98 (2014) e51–e56.
- [43] I. Kisu, M. Mihara, K. Banno, H. Hara, Y. Masugi, J. Araki, T. Lida, Y. Yamada, Y. Kato, T. Shiina, N. Suganuma, A. Aoki, A new surgical technique of uterine auto-transplantation in cynomolgus monkey: preliminary report about two cases, *Arch. Gynecol. Obstet.* 285 (2012) 129–137.
- [44] M. Mihara, I. Kisu, H. Hara, T. Iida, T. Yamamoto, J. Araki, Y. Hayashi, H. Moriguchi, M. Narushima, K. Banno, N. Suganuma, D. Aoki, I. Koshima, Uterus autotransplantation in cynomolgus macaques: intraoperative evaluation of uterine blood flow using indocyanine green, *Hum. Reprod.* 26 (2011) 3019–3027.
- [45] M. Mihara, I. Kisu, H. Hara, T. Iida, J. Araki, T. Shim, M. Narushima, T. Yamamoto, H. Moriguchi, Y. Kato, M. Tonsho, K. Banno, D. Aoki, N. Suganuma, N. Kagawa, Y. Takehara, O. Kato, I. Koshima, Uterine autotransplantation in cynomolgus macaques: the first case of pregnancy and delivery, *Hum. Reprod.* 27 (2012) 2332–2340.
- [46] I. Kisu, K. Banno, M. Mihara, H. Hara, K. Umene, M. Adachi, Y. Nogami, D. Aoki, A surgical technique using the ovarian vein in non-human primate models of potential living-donor surgery of uterus transplantation, *Acta Obstet. Gynecol. Scand.* 94 (2015) 942–948.
- [47] I. Kisu, M. Mihara, K. Banno, H. Hara, Y. Masugi, J. Araki, T. Lida, Y. Yamada, Y. Kato, T. Shiina, N. Suganuma, A. Aoki, Uterus allotransplantation in cynomolgus macaque: a preliminary experience with non-human primate models, *J. Obstet. Gynaecol. Res.* 40 (2014) 907–918.
- [48] C.A. Wranning, J. Mölne, R.R. El-Akouri, G. Kurlberg, M. Brännström, Short-term ischaemic storage of human uterine myometrium—basic studies towards uterine transplantation, *Hum. Reprod.* 20 (2005) 2736–2744.
- [49] G. Del Priore, J. Stega, K. Sieunarine, L. Ungar, J.R. Smith, Human uterus retrieval from a multi-organ donor, *Obstet. Gynecol.* 109 (2007) 101–104.
- [50] T. Gauthier, P. Piver, N. Pichon, R. Bibes, A. Guillaudeau, A. Piccardo, F. Pesteil, J. Tricard, E. Gardet, M. Laskar, F. Lalloué, P. Marquet, Y. Aubard, Uterus retrieval process from brain dead donors, *Fertil. Steril.* 102 (2014) 476–482.
- [51] L. Johannesson, C. Diaz-Garcia, H. Leonhardt, P. Dahm-Kähler, J. Marcickiewicz, M. Olausson, M. Brännström, Vascular pedicle lengths after hysterectomy: toward future human uterus transplantation, *Obstet. Gynecol.* 119 (2012) 1219–1225.
- [52] M. Erman Akar, O. Ozkan, B. Aydinuraz, K. Dirican, M. Cincik, I. Mendilcioglu, M. Simsek, F. Gunseren, H. Kocak, A. Gifcioglu, O. Gecici, O. Ozkan, Clinical pregnancy after uterus transplantation, *Fertil. Steril.* 100 (2013) 1358–1363.
- [53] S. Järholm, L. Johannesson, M. Brännström, Psychological aspects in pre-transplantation assessments of patients prior to entering the first uterus transplantation trial, *Acta Obstet. Gynecol. Scand.* 94 (2015) 1035–1038.
- [54] L. Johannesson, N. Kvarnström, J. Mölne, P. Dahm-Kähler, A. Enskog, C. Diaz-Garcia, M. Olausson, M. Brännström, Uterus transplantation trial: 1-year outcome, *Fertil. Steril.* 103 (2015) 199–204.
- [55] S. Järholm, L. Johannesson, A. Clarke, M. Brännström, Uterus transplantation trial: psychological evaluation of recipients and partners during the post-transplantation year, *Fertil. Steril.* 104 (2015) 1010–1015.
- [56] M. Brännström, C. Diaz-Garcia, L. Johannesson, P. Dahm-Kähler, H. Bokström, Livebirth after uterus transplantation—Authors replay, *Lancet* 385 (2015) 2352–2353.
- [57] M.C. Inhorn, Z.B. Gütin, Infertility and Assisted Reproduction in the Muslim Middle East: Social, Religious and Resource Considerations. FVV in ObGyn, *MONOGRAPH*, 2012, pp. 24–29.
- [58] A. Alghrani, Womb transplantation and the interplay of Islam and the West, *J. Relig. Sci., Zygon* 48 (2013) 618–634.
- [59] Islamic fiqh academy, resolutions and recommendations of the Council of the Islamic Fiqh Academy 1985–2000, first ed., Jeddah, 2000.
- [60] Catholic Church, Catechism of the Catholic Church, Rev. ed., Geoffrey Chapman, London, 1999, Paragraph 2376.
- [61] Father T. Pacholczyk, The National Catholic Bioethics Center in Philadelphia, 2015. <<https://www.osv.com/MyFaith/Bible/Article/TabId/671/ArtMID/13714/ArticleD/18761/Are-womb-transplants-immoral.aspx>> (accessed 24-11-2015).
- [62] J. Breck, *The Sacred Gift of Life: Orthodox Christianity and Bioethics*, first ed., Crestwood, New York, 2000, pp. 175–202.
- [63] S.S. Harakas, Embryo fertilization outside the womb, Contemporary moral issues facing the Orthodox Christian, Minneapolis, MN, 1982, pp. 88–92.
- [64] S.S. Harakas, The Orthodox Christian tradition. Religious beliefs and healthcare decisions. Part of the religious traditions and healthcare decisions handbook. Chicago, 1999, pp. 1–16.
- [65] E.N. Dorff, *Matters of Life and Death: A Jewish Approach to Modern Medical Ethics*, first ed., Jewish Publication Society, Philadelphia, 1998.
- [66] M. Olausson, L. Johannesson, D. Brattgård, C. Diaz-Garcia, C. Lundmark, K. Groth, J. Marcickiewicz, A. Enskog, R. Akouri, A. Tzakis, X. Rogiers, P.O. Janson, M. Brännström, Ethics of uterus transplantation with live donors, *Fertil. Steril.* 102 (2014) 40–43.